

Overlooked and Underdiagnosed: Sacroiliac Joint Dysfunction

W. Carlton Reckling, MD, and David W. Julian, BA, SI-BONE Inc., Santa Clara, California

Abstract

Sacroiliac (SI) joint dysfunction is routinely underdiagnosed. Many health care providers are not aware that the SI joint can be a pain generator. A true synovial joint, the SI joint, like the other major joints in the body, is subject to injury and degeneration.

SI joint pain is also commonly confused with other sources of low back, hip, or pelvis pain. In fact, studies have identified the SI joint as a pain generator in 15–30%^{1–5} of patients with chronic low back pain. In patients with continued or new onset pain after lumbar fusion, up to 43% of patients may have pain coming from the SI joint.⁶

Patients with chronic SI joint dysfunction have significant functional impairment. In fact, patients with chronic SI joint pain have a decrease in their quality of life that is as bad or worse than patients with other common musculoskeletal conditions that are treated surgically such as osteoarthritis of the hip and knee, spinal stenosis, and spondylolisthesis.⁷

Considering this context, how is the diagnosis of SI joint dysfunction made?

The first step is awareness that that SI joint can be a pain generator. The second step is following the diagnostic algorithm. Diagnosis requires a detailed patient history; hands-on physical examination of the lumbar spine, SI joint, and hip; imaging to rule out other pathologies; and a diagnostic injection to confirm the diagnosis. Input from health care providers who are knowledgeable about the diagnosis and treatment of SI joint dysfunction can be helpful.

Introduction: The Sacroiliac Joint

The sacroiliac (SI) joints (left and right) are part of the bony pelvic ring, linking the ilium to the sacrum. The SI joint provides stability for the pelvis and facilitates transfer of force from the torso to the lower extremities. It is the largest joint in the human body. It has an upper ligamentous portion, and the lower portion is a true synovial joint,^{8–10} with articular (hyaline) cartilage on both joint surfaces and a joint capsule with a synovial lining (Figure 1).

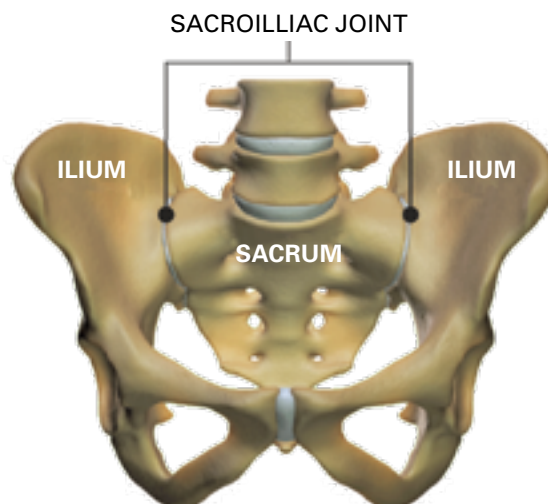
The SI joint moves (about 2–4 degrees) with normal daily activities^{11–15} and may be damaged from acute or repetitive trauma. The ligaments and soft tissues supporting the joint may be damaged, leading to abnormal force/load transfer. The joint may be affected by autoimmune, inflammatory, and/or infectious processes.¹⁶ It is also subject to degeneration secondary to osteoarthritis or increased stress at the joint (ie, adjacent segment disorder) after lumbar fusion.^{6,17–19}

Pathophysiology: Why does the SI joint hurt?

The SI joint is highly innervated, receiving nerve supply from dorsal nerve roots (L5-S3) and ventral nerve roots (S1-S4).^{20–25} Various pain fibers supply the SI joint, including free nerve endings, C fibers, and substance P and CGRP (calcitonin gene-related peptide) fibers.^{21,26,27} Pain fibers have been identified in the joint capsule, the cartilage, the subchondral bone, and the ligaments and muscles supporting the joint.

The SI joint moves to accommodate change in body position such as going from sitting to standing. Significant load (3 times body weight) is transferred across the SI joint.²⁸ When not functioning properly, the SI joint cannot appropriately

Figure 1 Pelvis image highlighting sacroiliac joints



transfer load and becomes painful. The inability to bear load may be related to damage to the articular cartilage, increased or decreased stiffness of ligaments, increased or decreased motion, altered joint position, or altered muscle function.²⁹

The cartilage of the SI joint is subject to the same internal and external processes that can damage the cartilage of other joints. It can be affected in ankylosing spondylitis or other inflammatory/autoimmune conditions.³⁰ The cartilage can be damaged secondary to acute or repetitive trauma or de novo degenerative osteoarthritis. Accelerated cartilage degeneration has been linked to repeated steroid injections in the hip and knee.^{31,32} This has not been studied in the SI joint but should be considered a risk.

Ligaments are an important component of SI joint stability. Ligaments are viscoelastic structures that change length in response to load.³³ Ligaments stretch when load is applied and return to normal length when the load is released.³⁴ Ligament stiffness can change secondary to trauma, pregnancy, and normal aging.³⁵⁻³⁹ The ability of the SI joint to accommodate load can be diminished in these cases. Asymmetry of SI joint ligament function is predictive of SI joint pain.⁴⁰

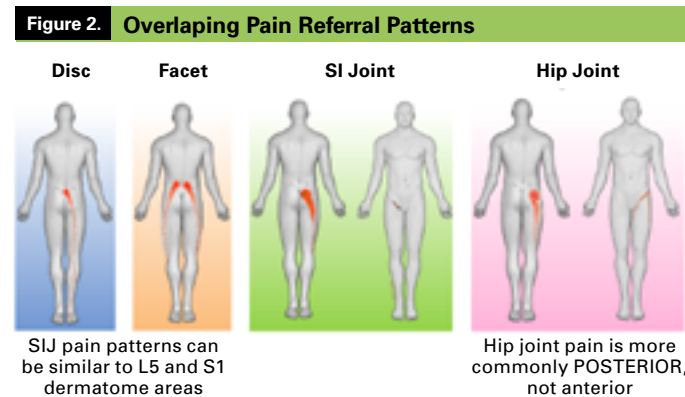
Pregnancy is a common cause of SI joint dysfunction. About 50% of women have pelvic girdle (frequently SI joint) pain during pregnancy and 25% experience pain after pregnancy.⁴¹ The ligaments supporting the SI joint are affected by the hormone relaxin,⁴² which softens the ligaments allowing the SI joints to widen to facilitate parturition. The ligaments often do not regain their prepregnancy stiffness and function.^{38,39} During vaginal delivery, 50% of women suffer damage to the soft tissues of the pelvic floor.⁴³ Many women experience chronic weakness of the abdominal musculature after pregnancy.^{39,44,45} The pelvic floor, abdominal, erector spinae, and diaphragm muscles comprise the core muscles that are vital to SI joint stability.⁴⁶ Approximately 5% of all pregnant women continue to have postpartum pelvic girdle pain or SI joint dysfunction 3 years after delivery.⁴⁷

Fusion of the spine results in stress transfer to the motion segments above and below the fusion. This stress can lead to damage at the adjacent levels and is described as adjacent segment degeneration. This is a recognized cause of SI joint dysfunction. In patients with continued or new onset pain after lumbar fusion, 32%-43% have pain from the SI joint.^{6,17,18,48} In a prospective study, 78% of patients with a lumbar fusion had radiographic evidence of SI joint degenerative changes 5 years later compared with 38% of age- and gender-matched controls without a fusion.¹⁹ Studies have shown that the higher the number of spinal levels fused, the higher the incidence of SI joint pain.⁴⁹

Diagnosis: Why is the SI joint routinely missed?

Health care providers are not regularly taught that the SI joint is a pain generator. In addition, the pain referral pattern for patients with SI joint pain is similar to pain patterns of the lumbar spine, hip, and pelvis. The same spinal nerves that innervate the lumbar spine structures (vertebrae, facets, disc, muscles) also innervate the bones and soft tissues supporting the SI joint and nearby structures in the hip and pelvis. The SI joint is involved in a significant percentage of patients with hip/groin pain.⁵⁰⁻⁵²

Up to 25% of patients presenting with chronic pelvic pain will have a musculoskeletal cause.^{53,54} Of these, a significant portion will involve the SI joint.^{29,55} Most providers do not typically consider the SI joint as part of the differential diagnosis during history and physical examination because SI joint pain patterns can look similar to facet joint, disc, and hip joint pain (Figure 2). The diagnostic pathway is a crucial



differentiator.^{6,24,56-60}

Another challenge is an overreliance on radiographic imaging. It is common to order imaging studies to rule out “red flag” conditions. Some diagnoses like disk herniation, spinal stenosis, or hip arthritis are easily made with imaging. In patients with chronic low back pain, an overreliance on imaging may result in interventions including surgery that do not address the correct underlying problem.⁶¹ Abnormal imaging findings in asymptomatic individuals are common in the spine.⁶²⁻⁶⁴ Abnormal radiographic findings in asymptomatic individuals have also been demonstrated in the knee and shoulder.⁶⁵⁻⁶⁷

Imaging of the SI joint has not been shown to be helpful in making the diagnosis of SI joint dysfunction. No imaging modality (X-ray, ultrasound, computed tomography, magnetic resonance imaging, bone scan, single-photon emission

computerized tomography [SPECT]) has been shown to be both sensitive and specific for the diagnosis of SI joint dysfunction.⁶⁸ A high percentage of individuals with no SI joint symptoms will have positive findings on imaging.⁶⁹ In addition, a patient with marked SI joint symptoms may demonstrate no SI joint findings on any imaging modality. Inflammatory arthropathy of the SI joints, in contrast, can be diagnosed on MRI and scintigraphic studies (bone scan, SPECT CT [computed tomography]).

Diagnostic algorithm for SI joint dysfunction

The diagnosis of SI joint dysfunction has been well validated. Several medical specialty societies and Health Technology Assessment organizations have published standardized diagnostic algorithms based on published clinical evidence.⁷⁰⁻⁷² The algorithms are remarkably consistent. They describe a focused patient history, including the Fortin finger test,⁷³ and a hands-on physical examination of the lumbar spine, SI joint, and hip. Imaging of the lumbar spine and pelvis is performed to rule out spinal pathology, hip pathology, and pathology of the SI joint such as tumor, infection, or inflammatory arthritis. Diagnosis is confirmed with an intra-articular diagnostic injection performed under fluoroscopic or CT guidance.

History: A patient history typically includes questions about prior trauma like a fall on the buttock, a car accident, or a lifting or twisting injury. A history of prior spinal surgeries, especially lumbar fusions or iliac bone grafts, is important. Has the patient been pregnant? Did she have low back pain during and/or after pregnancy? Patients may complain of lower extremity numbness, tingling, or weakness. Hip and groin pain are common. Is the patient unable to sit for long periods of time on one side? Finally, it’s important to ask if transitional movements cause the pain, like ascending/descending stairs, rolling over in bed, or getting in and out of bed.⁷⁴

Fortin finger test: One indicator of SI joint pain is simple: ask the patient to point directly to where it hurts. The patient will typically point to the area of the insertion of the long SI joint ligament near the posterosuperior iliac spine. The diagnostic algorithm, comprised of the Fortin finger test,⁷³ a patient history, and a physical examination including the 5 provocative maneuvers, is as good or better than the clinical diagnostic rules for lumbar conditions such as a herniated disc.⁷⁵

Physical examination of the lumbar spine: It is important to evaluate the lumbar spine when SI joint dysfunction is suspected. Examination of the spine includes visual inspection, palpation, range of motion testing, gait assessment, and

neurological examination including neural tension tests. The hands-on examination is important because physical findings should correlate with imaging results. Asymptomatic individuals may have abnormal imaging findings.⁶⁹

Physical examination of the hip: A hands-on examination begins with inspection and palpation of the hip and pelvis. Motion testing is important because loss of internal rotation is a sensitive finding.⁷⁶ Gait assessment is important. In addition, the hip Scour test for osteoarthritis,^{77,78} the FABER (Flexion ABduction External Rotation) test for intra-articular hip pathologies (if pain is anterior),⁷⁹ the FADIR (flexion, adduction, and internal rotation) test with hip flexion and adduction for labral tears,⁸⁰ and the FAIR (flexion, adduction, and internal rotation) test for piriformis syndrome (posterior hip pain),⁸¹ are all useful in identifying or ruling out the hip as the pain generator.

Physical examination of the SI joint: Palpate the sacral sulcus of the posterior superior iliac spine region and the insertion of the long dorsal ligament just inferior to the posterior superior iliac spine. Palpate the pubic symphysis, anterior hip capsule, greater trochanter, ischium, and the gluteus muscle. Assess gait and single leg stance. Functional tests like walking up stairs or going from sitting to standing can be helpful. The active straight leg raise test can assess pelvic stability. The patient is asked to lift their leg 20 cm off the examination table while lying supine.⁸² This test assesses the ability to transfer load from the limb across the SI joint to the pelvis.

Provocative maneuvers: A series of physical examination tests (provocative maneuvers) is used to stress the SI joint in different directions. They are typically performed by a specially trained health care provider such as a physical therapist, pain management physician, or surgeon. These maneuvers in combination have a high degree of sensitivity and specificity. If 3 of 5 of these maneuvers are positive (reproduce pain), the SI joint is likely the pain generator and SI joint dysfunction can be identified with up to 91% sensitivity and 78% specificity.⁸³⁻⁸⁷

SI joint dysfunction and the treatment team

Patients typically encounter several health care providers with different specialties during their diagnosis and treatment. Optimally the specialists work together to coordinate diagnosis and treatment of the patient. This ensures that the appropriate workup is performed and that unnecessary tests and interventions are avoided. A physical therapist and a pain management specialist are almost always part of the

team. A surgeon may manage these patients or may join the treatment team if nonsurgical treatments fail.

Your physical therapist

A physical therapist is helpful in confirming the diagnosis of SI joint dysfunction. Physical therapists are skilled in performing a musculoskeletal examination including the provocative maneuvers. Many of the studies on SI joint diagnosis have been published by physical therapists.^{75,83,84} Physical therapists play a key role in nonsurgical treatment. Most patients will benefit from a course of physical therapy. Physical therapists with manual therapy specialization are particularly skilled at treating SI joint dysfunction. A typical manual therapy approach includes identification of functional deficits and application of focused treatments to address these deficits. Most treatment algorithms from major societies like NASS (North American Spine Society) and ISASS (International Society for the Advancement of Spine Surgery) include physical therapy as a first-line intervention.^{70,71}

Your interventional pain physician

Many patients with SI joint dysfunction will interact with a pain specialist. A pain physician is the specialist who most frequently performs the diagnostic SI joint injection. The injection confirms the pain is coming from the SI joint.⁸⁸⁻⁹⁰ A small amount (2 mL) of local anesthetic, such as lidocaine, is injected under fluoroscopic or CT guidance into the articular portion of the SI joint. If this alleviates the patient's pain for a short period (1-4 hours), it is considered a positive diagnostic block. The diagnostic injection is not performed to cure the condition or to provide lasting relief, and it is important that the patient and the other care providers understand this point.

Pain management physicians often provide other treatments for SI joint dysfunction including steroid injections and radio frequency ablation of the nerves that supply the SI joint. There is no high-level evidence supporting the safety and effectiveness of SI joint steroid injections. Steroid injections typically provide weeks to months of pain relief. There are some risks of steroid injections, including accelerated cartilage degeneration with repeated injections.^{31,32} The cost effectiveness of this intervention has not been determined. There is no evidence to support repeated injections, and it is unknown how many injections are too many.

Radiofrequency ablation is another commonly performed intervention for SI joint pain. During this procedure, electricity is used to burn or freeze the sensory nerves that supply the back of the SI joint. The procedure has been shown to provide about 50% relief in 50% of patients for 6 months.^{91,92}

The nerves typically regenerate at 6 to 9 months. The safety and effectiveness of this procedure have been studied, and there is reasonable evidence to support the procedure.⁹¹⁻⁹⁴ No studies have demonstrated long-term pain relief or the benefit of repeating the procedure multiple times.

For patients who continue to have pain and diminished function following nonsurgical treatment, surgery may be an option. Minimally invasive SI joint fusion using a lateral trans-articular approach with placement of transfixing implants across the joint has been shown to be safe and effective.^{95,96} There is significant published clinical evidence including 2 randomized controlled trials^{97,98} and a prospective long-term study with results out to 5 years⁹⁹ that shows the procedure to be safe, effective, and durable. There are some allograft products on the market that are placed dorsally into the joint, but there is no published clinical evidence supporting the safety or effectiveness of these products or this surgical approach.

Key takeaways:

- **The SI joint is a pain generator.**
- **SI joint pain can present as low back pain, groin pain, hip pain, or pelvis pain.**
- **There is a standardized diagnostic algorithm for the diagnosis of SI joint pain.**

Recognizing that the SI joint can be a pain generator in patients presenting with low back and/or hip pain is essential to prevent misdiagnosis and to prevent the joint being overlooked entirely. Patients with chronic SI joint dysfunction have significant functional impairment and decreased quality of life that is as bad or worse than many other musculoskeletal conditions.

Awareness is the first step in getting the correct diagnosis of SI joint pain. The second is following a standardized diagnostic algorithm that includes a detailed patient history; hands-on physical examination of the lumbar spine, SI joint, and hip; imaging to rule out other pathologies; and a diagnostic injection to confirm the diagnosis. Finally, an SI joint treatment team will help provide efficient coordinated care. This team will help educate both the patient and other health care providers about the SI joint, allowing for faster diagnoses, informed care and treatment, and better patient outcomes. ■

[Click here for references.](#)

CEU exam

[Take this exam online >](#)

Take the test online and then immediately print your certificate after successfully completing the test. Or print, complete, and mail the exam on the next page.

Exam expires May 15, 2021.

This exam is FREE to all. [Click here to join ACCM](#) and get access to more CEs—up to 36 per year!

Overlooked and Underdiagnosed: Sacroiliac Joint Dysfunction

Questions

1. **The sacroiliac (SI) joints are part of the bony pelvic ring, linking the ilium to the sacrum.**
 - a. True
 - b. False
2. **What is the largest joint in the body?**
 - a. Knee joint
 - b. Hip joint
 - c. Sacroiliac joint
 - d. Ankle joint
3. **SI joint pain can present as:**
 - a. Low back pain
 - b. Groin pain
 - c. Hip pain
 - d. Pelvis pain
 - e. All of the above
4. **Which of the following processes can affect the SI joint?**
 - a. Autoimmune
 - b. Inflammatory
 - c. Infectious
 - d. All of the above
5. **When not functioning properly, the SI joint cannot appropriately transfer load and becomes painful.**
 - a. True
 - b. False
6. **SI joint pain is similar to what other joint pain?**
 - a. Lumbar spine
 - b. Hip
 - c. Pelvis
 - d. All of the above
7. **The diagnostic algorithm for SI joint pain includes:**
 - a. Patient history
 - b. Physical examination
 - c. Provocative measures
 - d. All of the above
8. **There is an overreliance on radiographic imaging when evaluating SI joint pain.**
 - a. True
 - b. False
9. **There is no high-level evidence supporting the safety and effectiveness of SI joint steroid injections.**
 - a. True
 - b. False
10. **Radiofrequency ablation or surgery may be a treatment option for SI joint pain.**
 - a. True
 - b. False

Take this exam online >

Take the test online and then immediately print your certificate after successfully completing the test. Or print, complete, and mail the exam on the next page. Exam expires May 15, 2021.

Overlooked and Underdiagnosed: Sacroiliac Joint Dysfunction

Objectives

May 2020

- a. State the function of the sacroiliac joint.
- b. Define the steps in diagnosing sacroiliac joint dysfunction.
- c. State 3 treatments in addressing sacroiliac joint dysfunction.

Answers

Please indicate your answer by filling in the letter:

1. _____ 2. _____ 3. _____ 4. _____ 5. _____ 6. _____ 7. _____ 8. _____ 9. _____ 10. _____

Continuing Education Program Evaluation

Please indicate your rating by circling the appropriate number using a scale of 1 (low) to 5 (high).

- | | | | | | |
|--|---|---|---|---|---|
| 1. The objectives were met. | 1 | 2 | 3 | 4 | 5 |
| 2. The article was clear and well organized. | 1 | 2 | 3 | 4 | 5 |
| 3. The topic was both relevant and interesting to me. | 1 | 2 | 3 | 4 | 5 |
| 4. The amount and depth of the material were adequate. | 1 | 2 | 3 | 4 | 5 |
| 5. The quality and amount of the graphics were effective. | 1 | 2 | 3 | 4 | 5 |
| 6. I would recommend this article. | 1 | 2 | 3 | 4 | 5 |
| 7. This has been an effective way to present continuing education. | 1 | 2 | 3 | 4 | 5 |
| 8. Additional comments: | | | | | |

Please print:

*Certificant's Name: _____

*Email Address: _____

*Mailing Address: _____

Please complete all that apply:

CCM ID# _____

CMSA ID# _____

CDMS ID# _____

RN ID# _____

ACCM Membership# _____

ACCM Exp. Date _____

*CE exams cannot be processed without above information.

CE contact hours applied for: CCM RN CDMS

This educational manuscript has been approved for 2 hours of CCM and CDMS education credit by The Commission for Case Manager Certification and the Certification of Disability Management Specialists Commission. Provider #00059431. It has also been approved for 2 contact hours of nursing credit by the California Board of Registered Nursing. To receive credit for this exam, you must score 80% or above. Exam expires May 15, 2021.

PLEASE NOTE: Exam may be taken online at academyCCM.org/ce or by clicking the link found in this supplement. Take the exam and immediately print your certificate after successfully completing the test. Mailed exams should be sent to: **Academy of Certified Case Managers, 1574 Coburg Road #225, Eugene, Oregon 97401.** Please allow 4 to 6 weeks for processing of mailed exams.

This CE exam is protected by U.S. Copyright law. You are permitted to make one copy for the purpose of exam submission. Multiple copies are not permitted.

If you are not an ACCM member and wish to become one, please [click here](#).